

be resolved using this small refinement in dressing technique.

DOI: 10.1097/01.PRS.0000136530.06899.92

Sophie M. Jones, M.A., M.R.C.S.
 Paul E. Banwell, F.R.C.S.
 Peter G. Shakespeare, Ph.D.
 Eunan Tiernan, F.R.C.S.
 Odstock Burns, Wound Healing, and Reconstructive Surgery
 Charitable Trust
 Laing Laboratory
 Salisbury District Hospital
 Salisbury, Wiltshire
 United Kingdom

Correspondence to Dr. Jones
 Odstock Burns, Wound Healing, and Reconstructive Surgery
 Charitable Trust
 Laing Laboratory
 Salisbury District Hospital
 Salisbury, Wiltshire SP2 8BJ
 United Kingdom
 sophie.jones@nhs.net

REFERENCES

- Banwell, P. E., Evison, D., and Whitworth, I. M. Vacuum therapy in degloving injuries of the foot: Technical refinements. *Br. J. Plast. Surg.* 55: 264, 2002.
- Joseph, E., Hamori, C. A., Bergman, S., Roaf, E., Swann, N. F., and Anastasi, G. W. A prospective randomised trial of vacuum-assisted closure versus standard therapy of chronic nonhealing wounds. *Wounds* 12: 60, 2000.
- DeFranzo, A. J., Argenta, L. C., Marks, M. W., et al. The use of vacuum-assisted closure therapy for the treatment of lower-extremity wounds with exposed bone. *Plast. Reconstr. Surg.* 108: 1184, 2001.
- Meara, J. G., Guo, L., Smith, J. D., Pribaz, J. J., Breuing, K. H., and Orgill, D. P. Vacuum-assisted closure in the treatment of degloving injuries. *Ann. Plast. Surg.* 42: 589, 1999.
- Azad, S., and Nishikawa, H. Topical negative pressure may help chronic wound healing. *B.M.J.* 324: 1100, 2002.
- Banwell, P. E., and Teot, L. Topical negative pressure (TNP): The evolution of a novel wound therapy. *J. Wound Care* 12: 22, 2003.
- Greer, S. E., Duthie, E., Cartolano, B., Koehler, K. M., Maydick-Youngberg, D., and Longaker, M. T. Techniques for applying subatmospheric pressure dressing to wounds in difficult regions of anatomy. *J. Wound Ostomy Continence Nurs.* 26: 250, 1999.
- Josty, I. C., Ramaswamy, R., and Laing, J. H. E. Vacuum-assisted closure: An alternative strategy in the management of degloving injuries of the foot. *Br. J. Plast. Surg.* 54: 363, 2001.
- Sposato, G., Molea, G., Di Caprio, G., Scioli, M., La Rusca, I., and Ziccardi, P. Ambulant vacuum-assisted closure of skin-graft dressing in the lower limbs using a portable mini-VAC device. *Br. J. Plast. Surg.* 54: 235, 2001.
- Morykwas, M. J., Argenta, L. C., Shelton-Brown, E. I., and McGuirt, W. Vacuum-assisted closure: A new method for wound control and treatment: Animal studies and basic foundation. *Ann. Plast. Surg.* 38: 553, 1997.
- Argenta, L. C., and Morykwas, M. J. Vacuum-assisted closure: A new method for wound control and treatment: Clinical experience. *Ann. Plast. Surg.* 38: 563, 1997.

REVERSAL OF EXPANDER PORT POLARITY FOLLOWING MAGNETIC RESONANCE IMAGING

Sir:

A 46-year-old woman was referred to me for possible breast reconstruction. After reviewing options with me in detail, she elected to have a McGhan Style 133MV 400-cc expander placed at the time of her right mastectomy. Injections proceeded normally for several months, but then at one visit the magnetic locator was being pushed away from, rather than pulled toward, the usual location of her port. I tried other locators, but they too were pushed away. When I explained to her what was occurring, she told me she had undergone magnetic resonance imaging of her other breast after her previous visit to my office. She said it was uneventful, and she never had any chest or other pains, never heard any unusual sounds, and felt no abnormal sensations. I then reversed the small magnetic piece in the port-finding device, and it immediately located her port in the usual location (with the end of the magnet that normally points away from the port). The patient's tissue expansion then continued uneventfully. At each subsequent visit I just had to reverse the magnetic piece on the port finder to locate her port.

In the September 1, 2002, issue of *Plastic and Reconstructive Surgery*, Dr. Lisa Sowder¹ reported a McGhan Style 133 400-cc expander port that became dislodged following magnetic resonance imaging. Like Dr. Sowder, I too advise my patients not to undergo magnetic resonance imaging while their expanders are in, but it is interesting that my patient's only adverse effect from the imaging procedure was a reverse in her expander port's magnetic polarity.

DOI: 10.1097/01.PRS.0000136533.60264.E8

Jeffrey A. Ascherman, M.D.
 Columbia University Medical Center
 161 Fort Washington Avenue
 New York, N.Y. 10032
 jaa7@columbia.edu

REFERENCE

- Sowder, L. L. The case of the floating injection port. *Plast. Reconstr. Surg.* 110: 991, 2002.

THE CASE FOR PERFORMING INITIAL BREAST AUGMENTATION PRIOR TO BILATERAL PROPHYLACTIC MASTECTOMY IN BRCA-1-POSITIVE PATIENTS

Sir:

There is a subsegment of breast cancer-negative patients who have small breasts and are *BRCA-1*-positive who are contemplating bilateral prophylactic mastectomy and reconstruction. An excellent option has been a skin-spar-

ing mastectomy followed by expander reconstruction. Although this is an acceptable and often gratifying form of reconstruction, the expansion process is arduous, prolonged, and often difficult for the patient. In addition, by its nature, the expansion process often occurs asymmetrically, requiring further revisions of the breasts. In selected patients who have small breasts and relatively good skin and who are contemplating prophylactic mastectomy, another alternative that should be considered is initial breast augmentation in a subpectoral location followed by skin-sparing prophylactic mastectomy 3 months later, to preserve the capsule and facilitate a purse-string-type (sun flap) closure.¹ We present a case of a 37-year-old woman who, 5 years earlier, had undergone breast augmentation with 450-cc saline breast implants. She was recently diagnosed with a right breast cancer, with three of 13 lymph nodes positive. A bilateral skin-sparing mastectomy with preservation of the capsules bilaterally and immediate reconstruction was performed, with sun flap closure of the periareolar tissues. Three months later, she underwent nipple-areola complex reconstruction followed by tattooing of the areola 1 month later (Fig. 1).

In conclusion, I believe that patients who have had breast augmentation and then are diagnosed with breast cancer, or those who are *BRCA-1*-positive, can be spared the process of expansion and can obtain a better-quality reconstruction by

first undergoing breast augmentation.

DOI: 10.1097/01.PRS.0000136531.14523.E4

Paul E. Chasan, M.D.
9850 Genesee Avenue
Suite 880
La Jolla, Calif. 92037

REFERENCE

1. Rahban, S. R., Wilde, M. K., and Chasan, P. E. Skin-sparing mastectomy with sun flap closure. *Ann. Plast. Surg.* 43: 452, 1999.

SUBCLINICAL INFECTION IN BREAST CAPSULES

Sir:

I read with interest the recent article published in the April 15, 2003, issue of *Plastic and Reconstructive Surgery* (111: 1605, 2003) entitled "Detection of Subclinical Infection in Significant Breast Capsules," by Pajkos et al. This has been a long-term research interest of ours.

Coagulase-negative staphylococci were originally believed to be "nonpathogenic," but as the authors point out, these organisms have been associated with clinical infections with increasing frequency, especially in operations using foreign

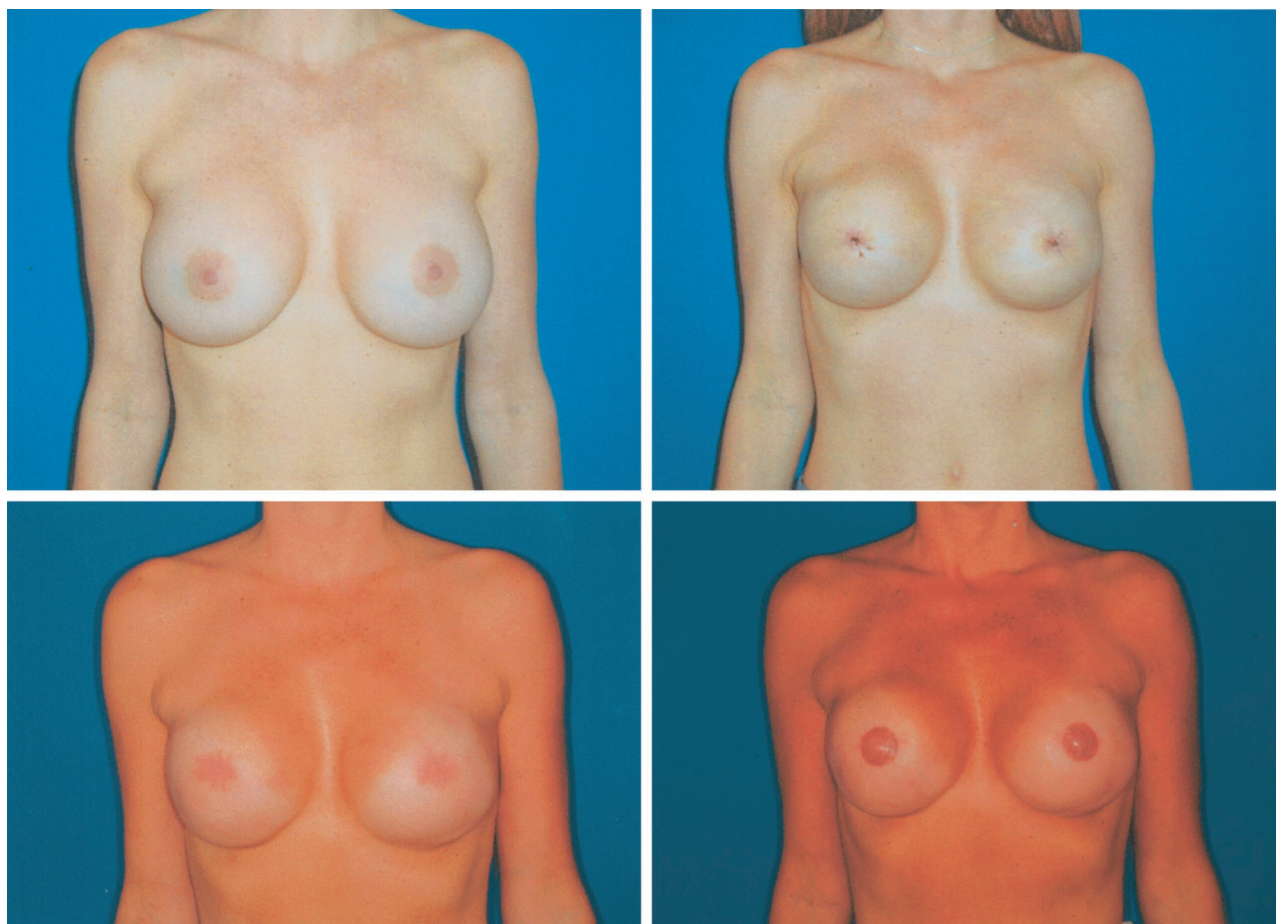


FIG. 1. (Above, left) Preoperative view. (Above, right) One month after bilateral skin-sparing mastectomy, implant exchange, bilateral lateral and inferior capsulorrhaphy, and sun flap closure. (Below, left) Three months postoperatively. (Below, right) Three months after bilateral nipple-areola complex reconstruction with modified C-V flap and nipple-areola tattooing.